Quest for Quality in Digital Cytopathology

Simone L. Van Es[1,2,3], Stephanie Gay[2], Janelle Greaves[3], Jennifer Ross[3], Tony Badrick[3], Derek Holzhauser[3]

[1]Department of Pathology, School of Medical Sciences, UNSW, Sydney, NSW, Australia;
[2]Royal College of Pathologists of Australasia, Surry Hills, NSW, Australia;
[3]Royal College of Pathologists of Australasia Quality Assurance Programs (RCPAQAP), St Leonards, NSW, Australia

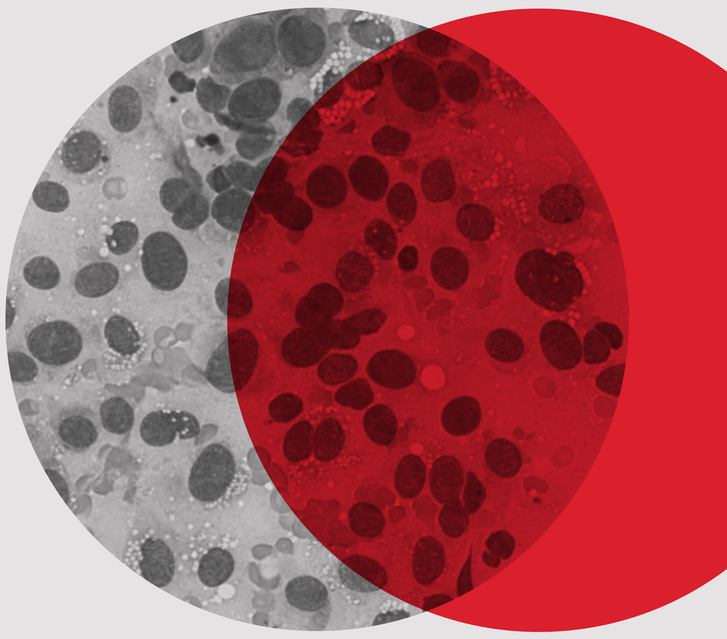

Digital surgical pathology is now universally accepted as equivalent to traditional microscopy for diagnostic accuracy but digital cytopathology is not. Reasons include:

- Cytopathology specimens contain three dimensional cell groups and dispersed cells at different focal planes.
- There are also a variety of cytological specimen types and preparation methods, the diversity of which can produce a challenge when digitising the glass slides.

Specimen and slide selection: What makes a good glass cytopathology slide also makes a good digital slide.

Need: Good cellular preservation, with glass slide and coverslip to be free of marks; ideally recent staining.

Avoid: Dense tissue fragments, heavily red cell-contaminated slides or overstained slides, clotted samples, scant material, plastic coverslips, material that is poorly spread, unevenly spread, thickly spread or over-cellular.

Preparation of the selected glass slide

Glass slides need:

- ✓ Cleaning with isopropyl alcohol then soft tissue wipes to remove dust, fingerprints and diagnostic screening marks
- ✓ Demarcating, defining or 'marking-up' of suitable areas on the glass slide prior to scanning

Scanning

Pap-stained wet fixed specimens usually contain cells in multiple focal planes and need z-stacking.

Editing

Checking the final WSI to identify problems and troubleshoot issues with the scanner or slide itself. WSI may be cropped to remove non-focused or non-diagnostic areas. Improve practitioner technique at specimen collection (e.g. minising trauma to reduce red blood cell contamination or removing fragments for embedding) and during laboratory preparations, based on the points above will improve quality of WSI.

Scanning technology

RCPAQAP's latest scanning technology (Metasystems/ Zeiss) analyses cell distribution topography.

This allows those specimens with a wide range of cell distribution focal planes to be rejected prior to scanning in z-axis.

"Sectra viewing solution: Metastatic lobular carcinoma" for the slide labelled Ascitic Fluid

"Sectra viewing solution: Mesothelioma" for the slide labelled Pleural fluid

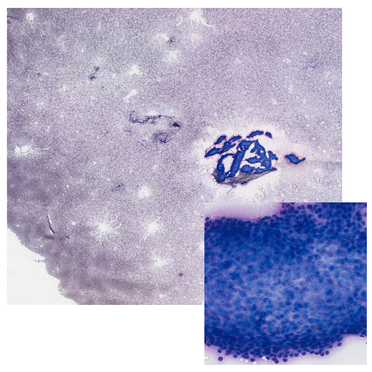

Dense tissue fragments are difficult to interpret on the resulting WSI (Glomus tumour-FNA arm , DQ, low power with high power insets,)



Two unevenly spread, thick and red blood cell-contaminated smears (Anaplastic large cell lymphoma - Breast and Small cell carcinoma - FNA sumandibular mass, DQ, low power with high power insets)



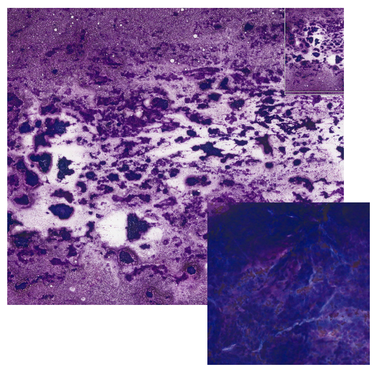

Thickly spread smear does not scan well (Papillary carcinoma - thyroid FNA, DQ, low power with high power inset)



Plastic coverslips often scratch during cleaning resulting in WSI quality issues. Note focus on scratched coverslip rather than the sample (Pap stain, high power with low power inset)

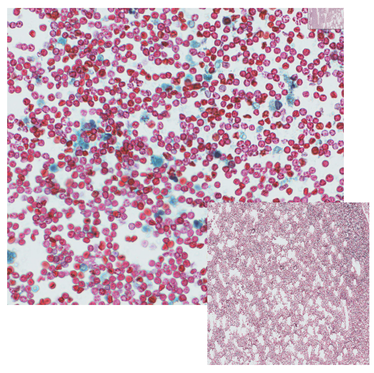

This Pap stained specimen (Cyst, FNA Thyroid) is heavily red blood cell-contaminated obscuring focus on diagnostic cells (high power with low power inset)

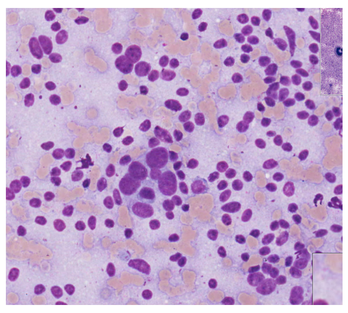

This FNA (neuroendocrine tumour - Lung,) is very cellular but evenly spread, producing good quality WSI

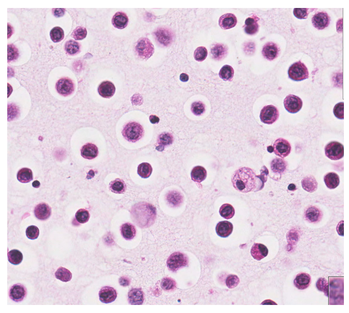

Cell blocks are presented mostly in a monolayer and scanning in x- and y-axes only may suffice (Metastatic gastric adenocarcinoma, H&E)

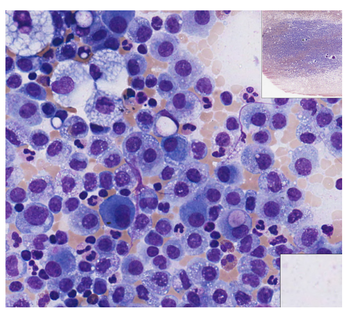

Air drying tends to flatten out cell collections and enlarge them, minimising the need for z-axis scanning (Metastatic adenocarcinoma, ascitic fluid, DQ)

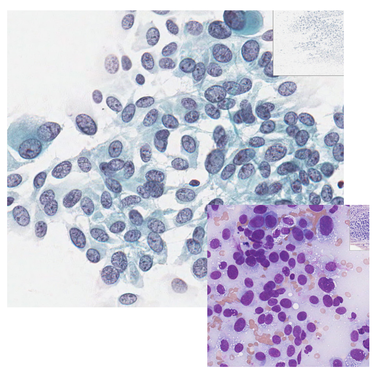

Ticks all the boxes: Well-spread, well-fixed, well-stained, resulting in high quality WSI even though cellular, (Metastatic melanoma FNA, Pap stain with DQ inset)

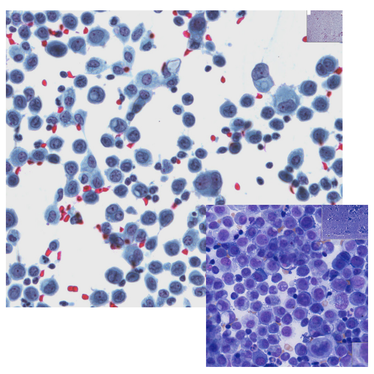

Very cellular but evenly spread resulting in high quality WSI (Metastatic lobular carcinoma-ascitic fluid, Pap stain, with DQ inset)

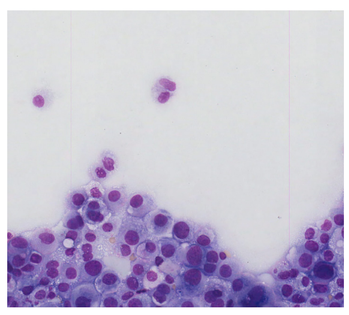

Editing: The cause of pink vertical lines needs to be identified and resolved (Metastatic ovarian carcinoma, -ascitic fluid, DQ)





Cell distribution analysis showing distribution of scant cellular diagnostic material across multiple focal planes in the z-axis (Carcinosarcoma, ascitic fluid, Pap stain, low power with high power inset)



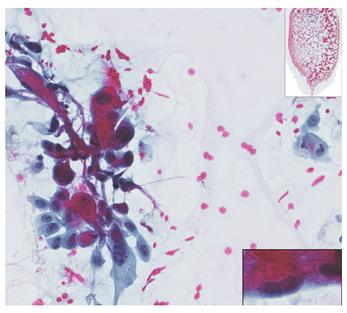

In contrast, narrower distribution planes of cellular material in the z-axis results in a flatter topography map and a better scan (Metastatic squamous cell carcinoma to bone,- FNA Pap high power with low power)